

# Innovative Design of the Silicone Stent Used in Dacryocystorhinostomies

RAZVAN HAINAROSIE<sup>1,2</sup>, TEODOR DAN POTECA<sup>1,4</sup>, OCTAVIAN CEACHIR<sup>1,2\*</sup>, DRAGOS CRISTIAN STEFANESCU<sup>3</sup>, CATALINA PIETROSANU<sup>1,2</sup>, VIOREL ZAINEA<sup>1,2</sup>

<sup>1</sup> Carol Davila University of Medicine and Pharmacy, 8 Eroii Sanitari Blvd., 050474, Bucharest, Romania

<sup>2</sup> Prof. Dr. D. Hociota Institute of Phonoaudiology and Functional ENT Surgery, 21 Mihail Cioranu Str., 050751, Bucharest, Romania

<sup>3</sup> Gen. Dr. Aviator Victor Anastasiu Institute of Aeronautical and Spatial Medicine, 88 Mircea Vulcanescu Str., 010825, Bucharest, Romania

<sup>4</sup> Colentina Clinical Hospital, Department of General Surgery, Bucharest, Romania, 19-21, Stefan cel Mare Blvd., 020125, Bucharest, Romania

*Endoscopic dacryocystorhinostomy (DCR) is a well-established treatment for epiphora caused by anatomic or functional obstruction of the nasolacrimal apparatus. A thorough understanding of the endonasal anatomy, wide marsupialization of the lacrimal sac, and meticulous care for the mucosa are critical for success. Nasal endoscopy has also facilitated the level of performance of the technique. The aim of this paper is to propose a new alternative for the dacryocystorhinostomy (DCR). The use of the new stent with a special design will give the surgeon the ability to keep the stent in the lacrimal duct as long as it is needed.*

**Key words:** silicone stent, dacryocystorhinostomy

Dacryocystorhinostomy (DCR) consists of a surgical procedure that creates an opening between the lacrimal duct and the nasal cavity at the level of the lacrimal crest [1]. That opening will allow the circulation of lacrimal secretions between the eye and the nostril [2]. The treatment of dacriocystitis has historical references that date to the 1st century CE.

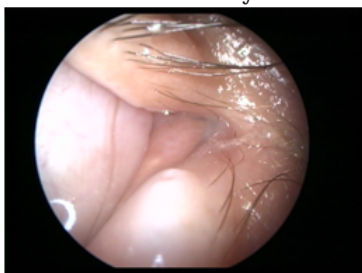


Fig. 1. External opening of the lacrimal duct

It was described by Celso, that reported that he created a passage between the eye and the nose using a cautery. Woolhouse in the 18th century described for the first time the external dacryocystorhinostomy.

In 1904 Toti has presented what we consider to be the modern description of DCR [3]. The first description of the endonasal DCR was made by Carter in 1893. In 1989, Heerman and Neues described the endonasal DCR using a microscope. McDonogh described for the first time in the same year the endonasal approach using the endoscope. LASER assisted DCR was described in 1990.

The technique was described as a major surgery. It involved important costs and prolonged hospital admittance. In our days DCR is considered to be a minimal invasive surgery that is performed as a one day surgery.

Some authors use stents, while some prefer not to use them [4,5]. The problem with the stent is that you can not control the period of time that the stent is stable in the correct position. For that reason we propose a new design of the DCR stent. The innovative design of the stent allows the surgeon to mount the stent in the classical manner, transnasally under endoscopic control, while enabling the surgeon to keep the stent in position as long as it is needed.

The removal of the stent can be easily performed under endoscopic control and in local anesthesia.

## Experimental part

Dacryocystorhinostomy is a minimally invasive surgery that is performed with general anesthesia and under endoscopic control. The surgical area is prepared using sponges with 1:100.000 epinephrine mounted for 10 minutes in the middle meatus, on the site of emergence of the sphenopalatine artery and on the inferior turbinate area.

If the patient presents an important nasal septum deviation that is located in the upper part of the nasal fossa, septoplasty may be necessary prior to DCR, during the same intervention.

Under the control of the 0° rigid endoscope we perform an inspection of the nasal fossa and localize the middle turbinate.

Anterior from the insertion of the middle turbinate we identify the position of the lacrimal crest. The epinephrine soaked sponges must be removed and local injections of a

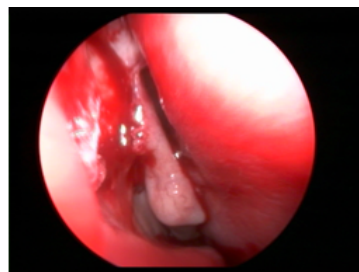

Fig. 2. Endoscopic examination of the nasal fossa

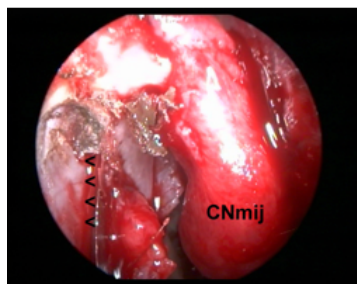


Fig. 3. Endoscopic examination - middle turbinate. Identifying the lacrimal crest

\* email: octavianceachir@gmail.com; Phone: 0727287182

All authors have contributed equally to this paper

vasoconstrictive substance are performed at the level of the axilla of the middle meatus and the frontal process of the maxilla.

Once the lacrimal crest is identified, we will perform an X shaped incision, which will allow us to create a number of 4 triangular shaped mucosal flaps. The lacrimal crest bone is then drilled using an endoscopic drill up to the point when the lacrimal duct is reached. An X shaped incision is made at the level of the exposed lacrimal duct and another 4 triangular shaped flaps are created.

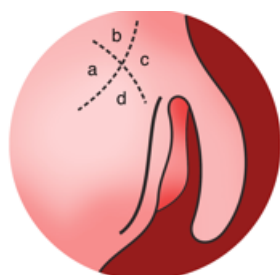


Fig. 4. The X shaped incision at the level of the lacrimal crest

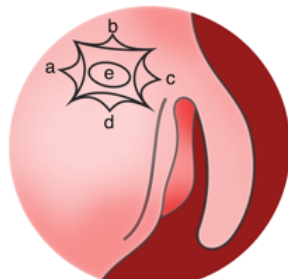


Fig. 5. The second incision with the triangular shaped flaps

A Bowman cannula is inserted externally through the inferior lacrimal puncta in order to verify the position of the lacrimal duct, until the cannula can be seen in the nose.

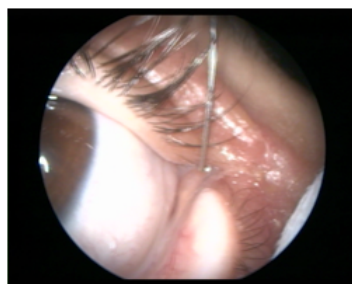

Fig. 6. External stenting of the lacrimal canal

In order to preserve the patency of the lacrimal duct, we consider appropriate to stent the duct.

The common stents have two disadvantages: the first problem is that the surgeon can not control the time that the stent is in place in the correct manner; the second problem is that the stent must be fixed with an endonasal suture that sometimes is difficult to perform.

We propose a new type of stent with an innovative design that can be inserted endonasally, does not need fixation with sutures and will be removed by the surgeon when he considers that it is no longer needed.

The innovative design of the new stent is represented by the addition of a round pyramidal shape area on the stent that has 3 orifices that allow the flow of tears. The pyramidal area is inserted with the tip upwards.

The base of the pyramid will provide a stable position for the stent. The 4 nasal mucosal flaps and the 4 lacrimal flaps will be placed in such manner that they will assure a good mucosa-to-mucosa apposition. The stent can be kept in place for 3-6 months and must be examined and controlled every month in order to assure the patency of the 3 orifices that will provide the lacrimal flow.

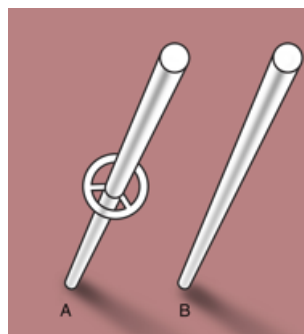


Fig. 7. (B) Normal stent and (A) the proposed innovative design

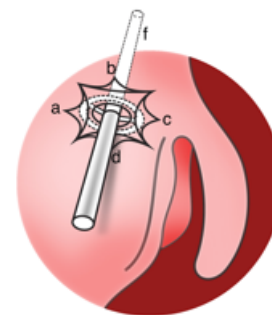


Fig. 8. The stent placed in its final position

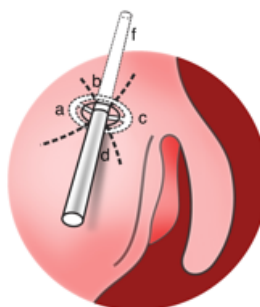


Fig. 9. Position of the stent with perfect apposition of the mucosal flaps

The considered material used in the composition of this device should be easily tolerated by the patient, and must be soft, but resistant enough to the movements and pressures exerted during the implanting process [6].

We selected polydimethylsiloxane as a safe material for manufacturing this device because it is cheap, transparent, has good mechanical properties and it is non-toxic. No mitomycin C was applied after the end of the surgery.

The patient is discharged the following day. Saline solution must be used to irrigate the nose, antibiotics are used for 7 days and eye drops with antibiotic and steroids are used for 2 weeks. Every 2 weeks the patient is examined and the crusts are removed.

After 3 or 6 months the tube is removed under endoscopic control by simply pulling the inferior part of the stent under local anesthesia.

## Results and discussions

The new design of the proposed DCR stent allows the surgeon to insert it easily trans nasally during an endoscopic approach. The pyramidal shaped design will provide a good fixation of the stent and the surgeon does not need to fixate it using additional sutures. The stent can be easily removed in local anesthesia under endoscopic control.

The selected material, polydimethylsiloxane is a good and safe option for manufacturing this device because it is cheap, transparent, has good mechanical properties and it is non-toxic. The polydimethylsiloxane stent is easily tolerated by the patient, is soft, but resistant enough to support the movements and pressures exerted during the implanting process.

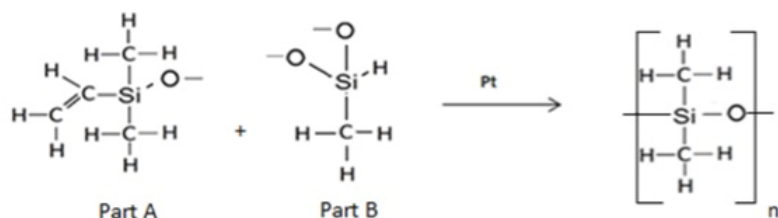


Fig. 10. Chemical reaction used for obtaining polydimethylsiloxane [6]

## Conclusions

In our experience, DCR achieves good long-term results if the surgeon maintains for 3 months the stent. The crusts must be removed in order to assure the lacrimal flow and the patency of the lacrimal duct. The design of the stent has the advantage of not requiring additional sutures for a good fixation.

Polydimethylsiloxane is a non toxic, cheap, soft but resistant material that can be used to construct the new DCR stent.

Due to the new design, the insertion of the stent can be done easily and the position of the stent is fixed and can only be removed by the surgeon when it is no longer required. The classical suture fixation is sometimes difficult to perform, which is why we underline the fact that the

design of the new stent eliminates the need for suture fixation. This translates into decreased time and costs of the anesthesia.

## References

- 1.HARTIKAINEN J., ANTILA J., VARPULA M., PUUKKA P., SEPPA H., GREMAN R. - Laryngoscope, 108, 1998, p1861.
- 2.MUSCATELLO L., GIUDICE M., SPRIANO G., TONDINI L. - Acta Otorhinolaryngol Ital., 25, nr. 4, 2005, p. 209.
- 3.TOTI A. - Clin Med Firenze, 10, 1904, p. 385.
- 4.ALLEN K., BERLIN A.J. - Ophtalm Surg, 20, 1989, p. 486.
- 5.WALLAND M.J., ROSE G.E. -Ophtalmic Surg., 25., 1994, p. 597.
- 6.A. COLAS - Dow Corning, technical document, MMV0995-01, 1995

---

Manuscript received: 23.12.2015